


Thyroid Ultrasound Training Phantom

Model 074



TEACH • TRAIN • PRACTICE

Thyroid nodules occur in 50% of the world's population with incidence increasing with age. Ultrasound guided biopsies of the thyroid yield more accurate results than free-hand techniques.¹

The CIRS Thyroid Training Phantom is a disposable training tool and practice medium for ultrasound guided thyroid biopsy procedures. The phantom also serves as an excellent teaching tool for identification of various types of thyroid nodules and training on proper thyroid scanning techniques.

This phantom contains a slightly enlarged thyroid gland positioned within an anthropomorphic neck. The chin and clavicle are provided as external anatomical landmarks. The phantom provides the trachea, internal jugular vein and common carotid artery as internal anatomical landmarks. Each thyroid lobe contains one cyst and one isoechoic stiff lesion. Various nodules can be manufactured within the thyroid gland on a custom basis. All materials are formulated to be ultrasonically realistic.

The phantom can be punctured numerous times, will not leak and requires no special storage.

The Thyroid Training Phantom creates a relaxed learning environment in which to develop skills.

Features

- Train how to perform thyroid ultrasound examination
- Practice ultrasound guided biopsy procedures
- Internal and external anatomical landmarks
- Ultrasonically realistic materials

¹ Cerutti JM, Delcelo R, Amadei MJ, Nakabashi C, Maciel RM, Peterson B, Shoemaker J, Riggins GJ. "A preoperative diagnostic test that distinguishes benign from malignant thyroid carcinoma based on gene expression." J Clin Invest. 2004 Apr; 113(8): 1234-42.

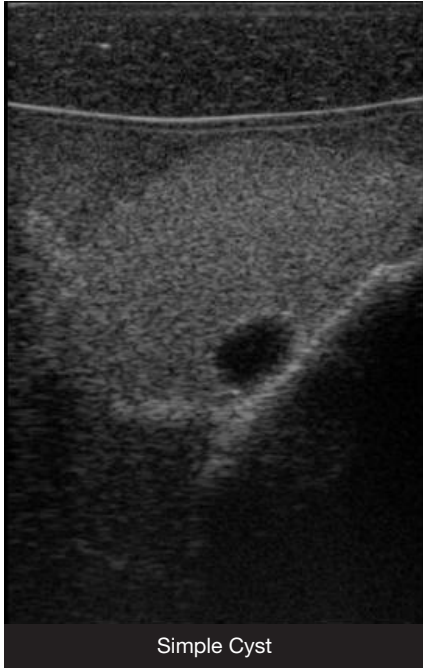
900 Asbury Ave • Norfolk, Virginia 23513 • USA
Tel: 800.617.1177 • 757.855.2765 • Fax: 757.857.0523

WWW.CIRSINC.COM

CIRS

Tissue Simulation & Phantom Technology

THYROID ULTRASOUND TRAINING PHANTOM



Simple Cyst

The slightly enlarged thyroid gland contains simple cysts and one isoechoic, stiff lesion in each lobe.

Fine needle aspiration can be performed on each cyst. Each stiff lesion is designed for visualization with sonoelastography and can be biopsied. These lesions are isoechoic to the thyroid gland and with standard B-mode imaging.

Nodules that represent adenocarcinomas, calcifications or papillary carcinomas ranging in size from 6-15 cm are available by custom request only.

SPECIFICATIONS

OVERALL DIMENSIONS	31 cm x 32.5 cm (12.2" x 12.8")
WEIGHT	9.4 lbs (3.5 kg)
MATERIALS	Outside: Z-Skin™ elastomer Internal: Zerdine®
INTERNAL STRUCTURE	Jugular Vein Common Carotid Artery Trachea with (2) cysts and (2) isoechoic, stiff lesions

MODEL 074 INCLUDES

QTY	COMPONENT DESCRIPTION
1	Thyroid Ultrasound Training Phantom
1	User Guide
-	6-Month Warranty